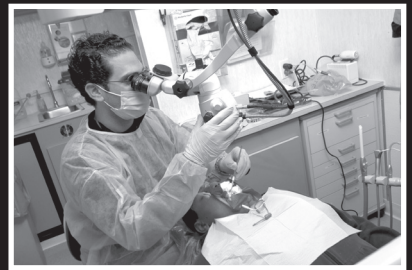
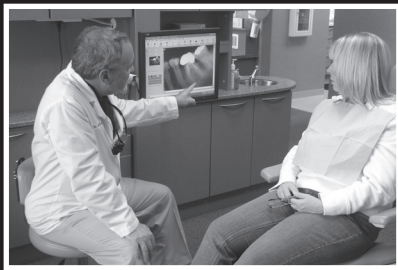


New Edition



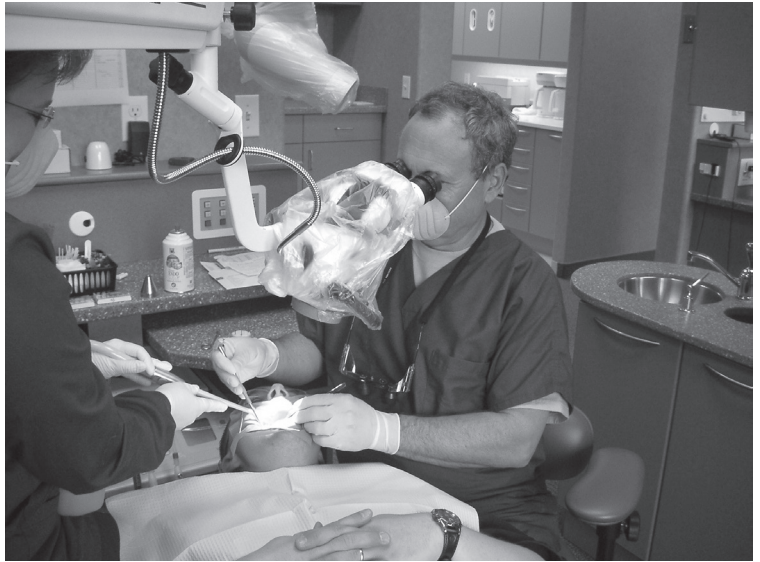Treatment Options for the Compromised Tooth

A Decision Guide



TREATMENT PLANNING CONSIDERATIONS

The *Treatment Options for the Compromised Tooth* decision guide features different cases where the tooth has been compromised in both nonendodontically treated teeth and previously endodontically treated teeth. Based on the unique individualized features of each case and patient, there are key considerations in establishing a preoperative prognosis of Favorable, Questionable or Unfavorable.



If your patient's condition falls into a category other than Favorable, referral to an endodontist, who has expertise on alternate treatment options that might preserve the natural dentition, is recommended. If the prognosis of the tooth is categorized as Questionable/Unfavorable in multiple areas of evaluation, extraction should be considered after appropriate consultation with a specialist.

In making treatment planning decisions, the clinician also should consider additional factors including local and systemic case-specific issues, economics, the patient's desires and needs, aesthetics, potential adverse outcomes, ethical factors, history of bisphosphonate use and/or radiation therapy.

Although the treatment planning process is complex and new information is still emerging, it is clear that appropriate treatment must be based on the patient's best interests.

© Copyright 2011
American Association of Endodontists
211 E. Chicago Ave., Suite 1100
Chicago, IL 60611-2691
Phone: 800/872-3636 (North America) or 312/266-7255 (International)
Fax: 866/451-9020 (North America) or 312/266-9867 (International)
E-mail: info@aae.org Website: www.aae.org

Root Amputation, Hemisection, Bicuspidization

The photographs/radiographs below illustrate favorable outcomes for our patients.

Treatment Considerations/Prognosis

Remaining Coronal Tooth Structure

Favorable: >1.5 mm ferrule

Questionable: 1.0 to 1.5 mm ferrule

Unfavorable: <1 mm ferrule

Crown Lengthening

Favorable: None needed

Questionable: If required will not compromise the aesthetics or periodontal condition of adjacent teeth

Unfavorable: Treatment required that will affect the aesthetics or further compromise the osseous tissues (support) of the adjacent teeth

Endodontic Treatment

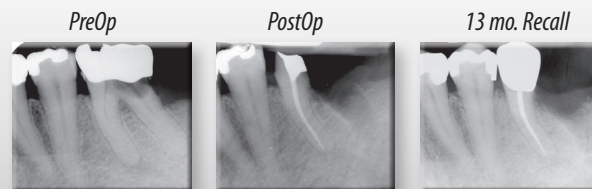Favorable: Routine endodontic treatment or not required due to previous treatment

Questionable: Nonsurgical root canal retreatment required prior to root resection

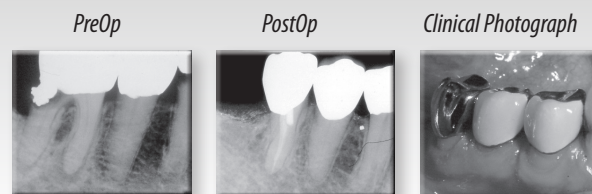
Unfavorable: Canal calcification, complex canal and root morphology, and isolation complicate an ideal endodontic treatment result

Hemisection and crown lengthening

Case One
Hemisection of the distal root of tooth #19



Case Two*
Hemisection of the distal root of tooth #30



*These images were published in *The Color Atlas of Endodontics*, Dr. William T. Johnson, p. 162, Copyright Elsevier 2002.

Endodontic-Periodontic Lesions

The photographs/radiographs below illustrate favorable outcomes for our patients.

Treatment Considerations/Prognosis

Periodontal Conditions

Favorable: Normal periodontium

Normal probing depths (3mm or less)

The tooth exhibits pulp necrosis and isolated bone loss to the involved tooth or root

Questionable: Moderate periodontal disease

An isolated periodontal probing defect

The tooth exhibits pulp necrosis and moderate bone loss

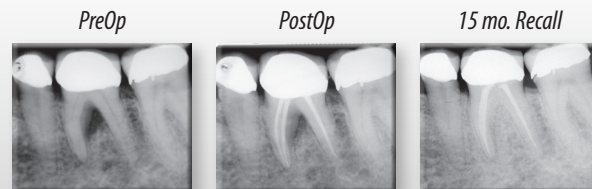Unfavorable: Advanced periodontal disease

Generalized periodontal probing defects throughout the patient's mouth

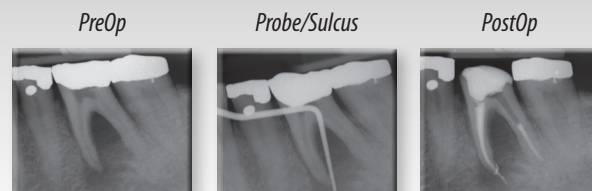
The tooth exhibits pulp necrosis and there is generalized bone loss (horizontal and/or vertical)

Extensive endodontic-periodontic lesions, complete healing

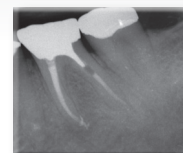
Case One
Tooth #19 exhibiting a localized mesial furcation defect; there is no probing defect



Case Two
Tooth #19 with extensive osseous destruction; there is sulcular communication and a deep isolated probing defect



24 mo. Recall



External Resorption

The photographs/radiographs below illustrate favorable outcomes for our patients.

Treatment Considerations/Prognosis

External Resorption

Favorable: Minimal loss of tooth structure

Located cervically but above the crestal bone

The lesion is accessible for repair

Apical root resorption associated with a tooth exhibiting pulp necrosis and apical pathosis

Questionable: Minimal impact on restorability of tooth

Crown lengthening or orthodontic root extrusion may be required

The pulp may be vital or necrotic

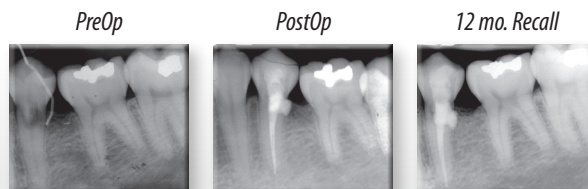
Unfavorable: Structural integrity of the tooth or root is compromised

There are deep probing depths associated with the resorptive defect

The defect is not accessible for repair surgically

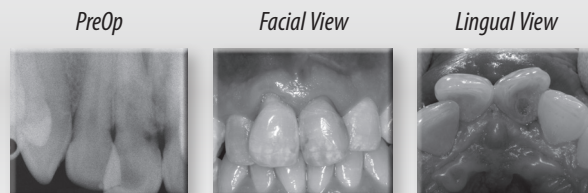Case One

External resorption with sinus tract, with ≤ 3 mm probings; MTA internal repair after 2 weeks CaOH, root canal treatment and 12-month recall with resolution of sinus tract



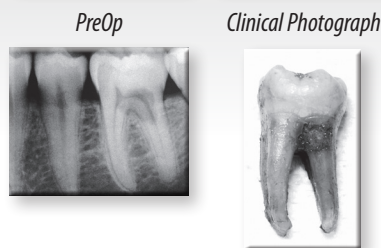
Case Two

External resorption on the mesial of the maxillary right central incisor; there is a periodontal probing defect on the mesiolingual



Case Three

Tooth #19 unfavorable prognosis; there is a large cervical resorptive defect on the buccal aspect of the distal root extending into the furcation



Internal Resorption

The photographs/radiographs below illustrate favorable outcomes for our patients.

Treatment Considerations/Prognosis

Internal Resorption

Favorable: Small/medium defect

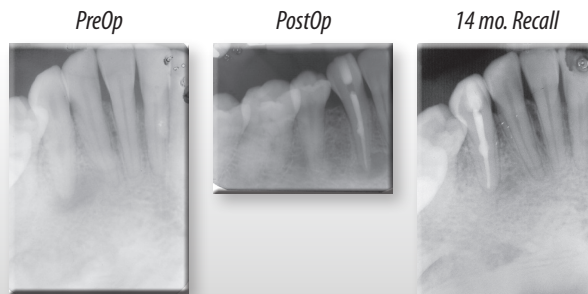A small lesion in the apical or mid-root area

Questionable: Larger defect that does not perforate the root

Unfavorable: A large defect that perforates the external root surface

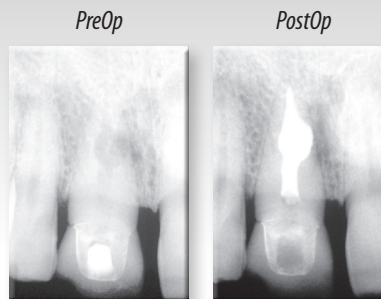
Case One

Tooth #28 exhibiting a mid-root internal resorptive defect



Case Two

Tooth #8 exhibiting an apical to mid-root internal resorptive lesion



Tooth Fractures

The photographs/radiographs below illustrate favorable outcomes for our patients.

Treatment Considerations/Prognosis

Crown Fractures

Favorable: Coronal fracture of enamel or dentin not exposing the pulp; coronal fracture of enamel and dentin exposing the pulp of a tooth with mature root development

Questionable: Coronal fracture of enamel and dentin exposing the pulp with immature root development

Unfavorable: Coronal fracture of enamel or enamel and dentin extending onto the root below the crestal bone; compromised restorability requiring crown lengthening or orthodontic root extrusion

Horizontal Root Fractures

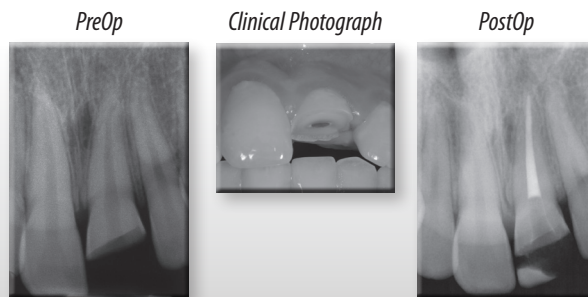
Favorable: The fracture is located in the apical or middle third of the root; there is no mobility; the pulp is vital (note in the majority of root fractures the pulp retains vitality)

Questionable: The fracture is located in the coronal portion of the root and the coronal segment is mobile; there is no probing defect; the pulp is necrotic; a radiolucent area is noted at the fracture site

Unfavorable: The fracture is located in the coronal portion of the root and the coronal segment is mobile; there is sulcular communication and a probing defect

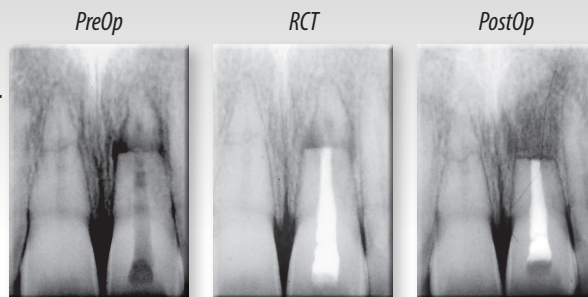
Crown Fracture

Tooth #8 exhibiting a complicated coronal fracture, root canal treatment and bonding of the coronal segment



Horizontal Root Fracture*

Horizontal root fractures of #8 and #9; the maxillary right central remained vital while the maxillary left central developed pulp necrosis requiring nonsurgical and surgical root canal treatment; prognosis favorable



*These images were published in *The Color Atlas of Endodontics*, Dr. William T. Johnson, p. 176, Copyright Elsevier 2002.

Tooth Fractures

The photographs/radiographs below illustrate favorable outcomes for our patients.

Treatment Considerations/Prognosis

Cracked Tooth

Favorable: Fracture in enamel only (crack line) or fracture in enamel and dentin

The fracture line does not extend apical to the cemento-enamel junction

There is no associated periodontal probing defect

The pulp may be vital requiring only a crown

If pulp has irreversible pulpitis or necrosis, root canal treatment is indicated before the crown is placed

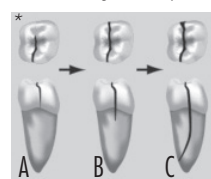
Questionable: Fracture in enamel and dentin

The fracture line may extend apical to the cemento-enamel junction but there is no associated periodontal probing defect

There is an osseous lesion of endodontic origin

Unfavorable: Fracture line extends apical to the cemento-enamel junction extending onto the root with an associated probing defect

Cracked Tooth Progression To Split Tooth

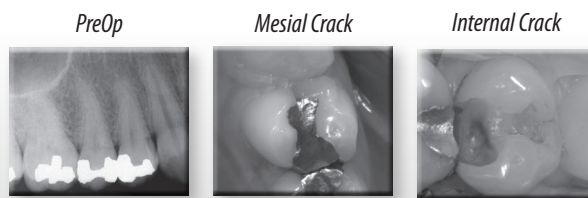


A – Favorable prognosis
B – Questionable prognosis
C – Split tooth, Unfavorable prognosis

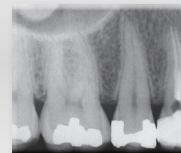
*Reprinted with permission from Tarabinejad and Walton, *Endodontics: Principles and Practice 4th ed*, Saunders/Elsevier 2009.

Case One

Fracture in mesial marginal ridge #5, stopping coronal to pulp floor

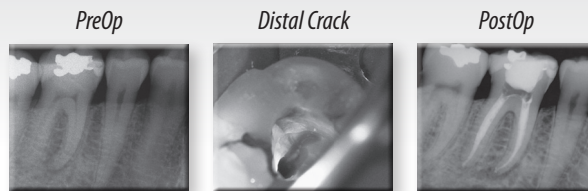


PostOp



Case Two

Tooth #30 exhibiting pulp necrosis and asymptomatic apical periodontitis; a crack was noted on the distal aspect of the pulp chamber under the composite during root canal treatment



Apical Periodontitis

The photographs/radiographs below illustrate favorable outcomes for our patients.

Treatment Considerations/Prognosis

Apical Periodontitis

The presence of periapical radiolucency is not an absolute indicator of a poor long-term prognosis. The vast majority of teeth with apical periodontitis can be expected to heal after nonsurgical or surgical endodontic treatment. Data indicate the presence of a lesion prior to treatment only decreases the prognosis slightly.

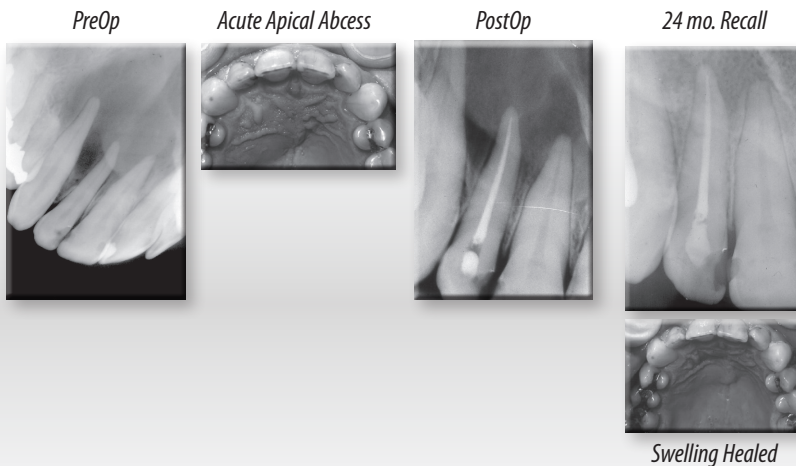
Favorable: Pulp necrosis with or without a lesion present that responds to nonsurgical treatment

Questionable: Pulp necrosis and a periapical lesion is present that does not respond to nonsurgical root canal treatment but can be treated surgically

Unfavorable: Pulp necrosis and a periapical lesion is present that does not respond to nonsurgical root canal treatment or subsequent surgical intervention

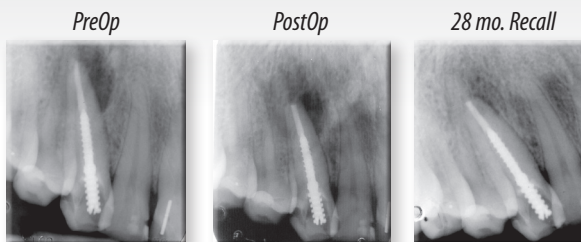
Case One

A large periapical lesion resulting in an acute apical abscess resulting from pulp necrosis of tooth #7



Case Two

Tooth #6 exhibiting a large lesion, apical surgery, complete healing



Procedural Complications

The photographs/radiographs below illustrate favorable outcomes for our patients.

Treatment Considerations/Prognosis

Nonsurgical Root Canal Retreatment

Favorable: The etiology for failure of the initial treatment can be identified; nonsurgical endodontic retreatment will correct the deficiency

Questionable: The etiology for failure of the initial treatment cannot be identified; nonsurgical endodontic retreatment may not correct the deficiency

Unfavorable: The etiology for failure of the initial treatment cannot be identified and corrected with nonsurgical retreatment and surgical treatment is not an option

Altered Anatomy/Procedural Complications (e.g., loss of length, ledges, apical transportation)

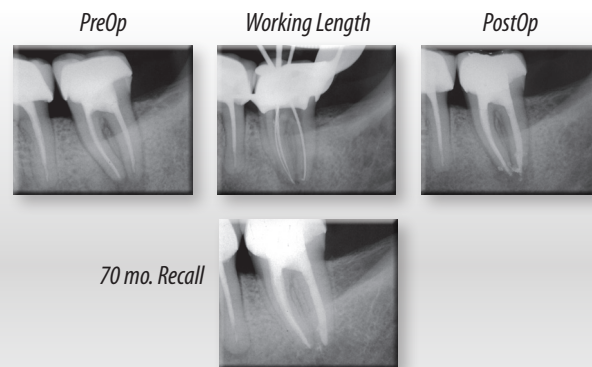
Favorable: The procedural complication can be corrected with nonsurgical treatment, retreatment or apical surgery

Questionable: Canals debrided and obturated to the procedural complication, there is no apical pathosis and the patient is followed on recall examination

Unfavorable: The patient is symptomatic or a lesion persists and the procedural complication cannot be corrected and the tooth is not amenable to surgery (apicoectomy/intentional replantation)

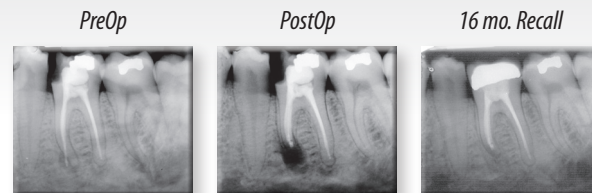
Nonsurgical Root Canal Retreatment*

Tooth #18 is symptomatic and exhibiting apical pathosis



Altered Anatomy

Surgical treatment of tooth #19 to correct apical transportation in the mesial root



*Reprinted with permission from DENTSPLY/AAE Lecture series, "Endodontic Team Care: Educating Your Referral Network - Diagnosis and Treatment Planning."

Procedural Complications

The photographs/radiographs below illustrate favorable outcomes for our patients.

Treatment Considerations/Prognosis

Separated Instruments

Favorable: No periapical periodontitis

In general, success/failure rates for cases that have a separated instrument in the apical one-third of the root have favorable outcomes

Able to retrieve nonsurgically or surgically if periapical pathosis is present

Defect correctable with apical surgery

Questionable: Instruments fractured in the coronal or mid-root portion of the canal and cannot be retrieved

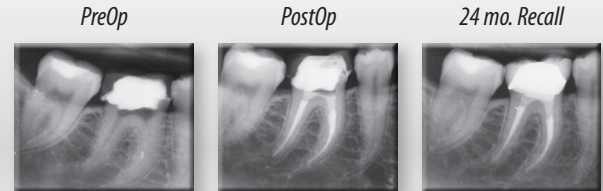Patient asymptomatic

No periapical periodontitis

Unfavorable: The patient is symptomatic or a lesion persists requiring extensive procedures in order to retrieve instrument that would ultimately compromise long-term survival of the tooth and surgical treatment is not an option (apicoectomy/intentional replantation)

Separated Instrument

Tooth #30 exhibiting a fractured instrument in the mesial root; recall examination demonstrates a successful outcome



Treatment Considerations/Prognosis

Perforations—Location

Favorable: Apical with no sulcular communication or osseous defect

Questionable: Mid-root or furcal with no sulcular communication or osseous defect

Unfavorable: Apical, crestal or furcal with sulcular communication and a probing defect with osseous destruction

Perforations—Time of Repair

Favorable: Immediate repair

Questionable: Delayed repair

Unfavorable: No repair or gross extrusion of the repair materials

Perforations—Size

Favorable: Small (relative to tooth and location)

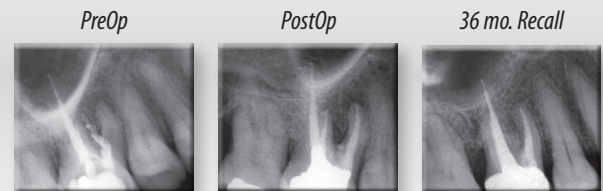Questionable: Medium

Unfavorable: Large

Perforations

Case One

Tooth #3 exhibiting a coronal perforation which is repaired with MTA in conjunction with nonsurgical root canal treatment



Procedural Complications

The photographs/radiographs below illustrate favorable outcomes for our patients.

Treatment Considerations/Prognosis

Post Perforation

Favorable: No sulcular communication or osseous destruction

Questionable: No sulcular communication but osseous destruction is evident

The perforation can be repaired surgically

Unfavorable: Long standing with sulcular communication, a probing defect and osseous destruction

Strip Perforation

Favorable: Small with no sulcular communication

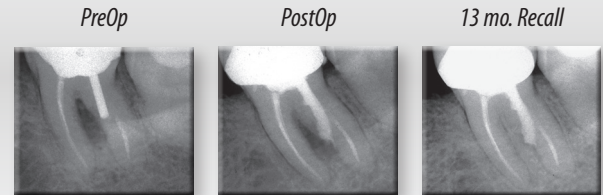Questionable: No sulcular communication and osseous destruction that can be managed with internal repair or surgical intervention

Unfavorable: Sulcular communication and osseous destruction that cannot be managed with internal repair or surgical intervention

Perforations

Case Two

Tooth #18 exhibiting a post perforation in the distal root with post removal and MTA repair; note the osseous regeneration in the furcation on the recall examination



Retreatment: Post Removal, Silver Points, Paste

The photographs/radiographs below illustrate favorable outcomes for our patients.

Treatment Considerations/Prognosis

Posts

With the use of modern endodontic techniques, most posts can be retrieved with minimal damage to the tooth and root. Ceramic posts, fiber posts, threaded posts, cast posts and cores, and proprietary posts placed with resins are most challenging to remove. In some instances the post may not have to be removed and the problem can be resolved by performing root-end surgery (apicoectomy).

Favorable: Proprietary cylindrical stainless steel posts placed with traditional luting cements such as zinc phosphate

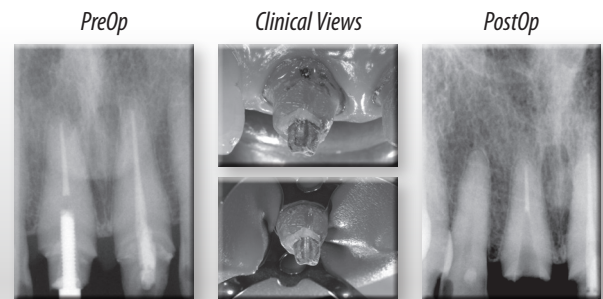
Questionable: Cast post and cores placed with traditional luting cements such as zinc phosphate

Unfavorable: Proprietary posts (stainless steel or titanium), cast post and cores placed with bonded resins; threaded, fiber and ceramic posts that cannot be removed or removal compromises the remaining tooth structure

Teeth that cannot be retreated or treated surgically have an unfavorable prognosis

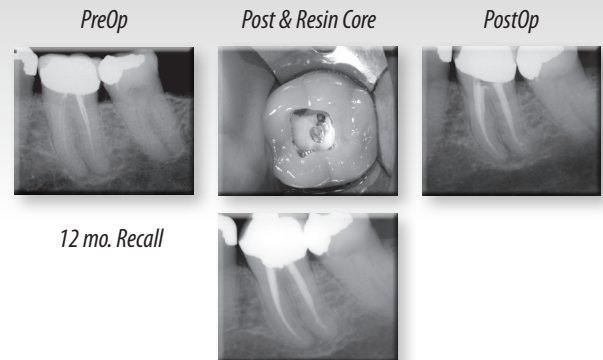
Case One

Tooth #8 requiring removal of a proprietary post



Case Two

Tooth #19 demonstrating incomplete obturation and a threaded post placed with a bonded resin core



Retreatment: Post Removal, Silver Points, Paste

The photographs/radiographs below illustrate favorable outcomes for our patients.

Treatment Considerations/Prognosis

Silver Points – Silver points were a popular core obturation material in the 1960s and early 1970s. While their stiffness made placement and length control an advantage, the material did not fill the canal in three dimensions resulting in leakage and subsequent corrosion.

Carrier Based Systems – Carrier-based thermoplastic (e.g., Thermafil) systems are similar to silver cones. The core material originally was metal, but has been replaced with plastic. They can generally be removed as the gutta-percha can be softened with heat and solvents facilitating removal.

Favorable: Silver cones that extend into the chamber facilitating retrieval and have been cemented with a zinc-oxide eugenol sealer

Plastic carrier-based thermoplastic obturators

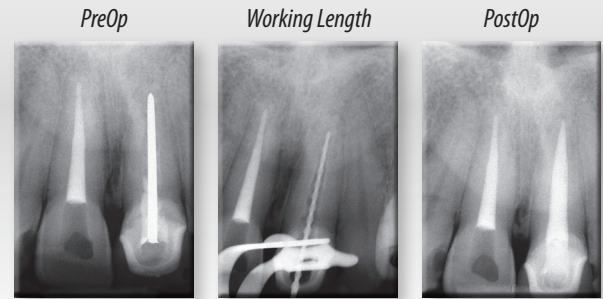
Questionable: Silver cones that are resected at the level of the canal orifice or have been cemented with zinc phosphate or polycarboxylate cement

Silver cones that can be bypassed or teeth that can be treated surgically

Unfavorable: Sectional silver cones were placed apically in the root to permit placement of a post; if they cannot be retrieved or bypassed and the tooth is not a candidate for surgical intervention the prognosis is unfavorable

Silver Point Retreatment

Tooth #9 treated 25 years ago requiring retreatment



Treatment Considerations/Prognosis

Previously Used Root-Filling Materials

With the use of modern endodontic techniques most filling materials can be retrieved with minimal damage to the tooth and root. In some instances the filling materials may not have to be removed and the problem can be resolved by performing root-end surgery (apicoectomy).

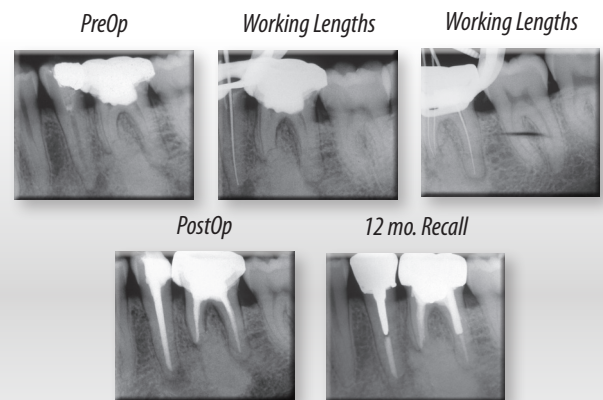
Favorable: Soft or soluble pastes, pastes in the chamber or coronal one-third of the root that are removed easily

Questionable: Hard insoluble pastes in the chamber extending into the middle-third of the root

Unfavorable: Hard insoluble pastes placed into the apical one-third of the root that cannot be retrieved and the tooth is not amenable to surgical intervention (apicoectomy/intentional replantation)

Case One

Previous paste treatment of tooth #19 and tooth #20



Case Two

Tooth #18 with a hard insoluble paste and a periradicular lesion

